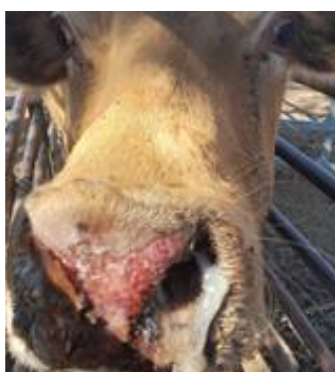




## Clinical signs of Epizootic Haemorrhagic Disease

### Clinical signs of Epizootic Haemorrhagic Disease (EHD)

- Fever
- Anorexia, Inappetance
- Lesions on the muzzle and lips
- Swelling of the head and neck
- Drop in milk yield
- Reddening of the mucus membranes
- Sores on the nose, gums and dental pads
- Respiratory distress
- Drooling, Dysphagia (difficulty swallowing)
- Discharge from the eyes and/or nose
- Lameness
- Abortion or deformities in offspring
- Haemorrhages in many tissues including the skin and heart
- Possible death (in severe cases)




*Fig.1 nasal discharge with crusting and redness of muzzle*



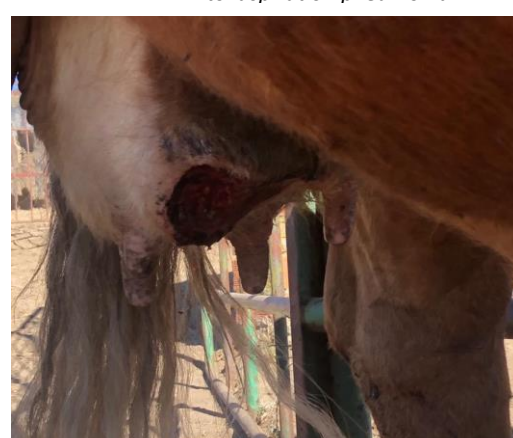*Fig. 2 Erosions on dental pad can cause excessive drooling and difficulty eating. These lesions be confused with Foot and Mouth Disease lesions*



*Fig.3 EHD can cause dullness and depression, with high temperatures, discharge from the eyes and nose. Damage and swelling of the tongue and the muscles in the neck can lead to aspiration pneumonia*



*Fig.4 EHD can cause damage to small blood vessels leading to erosions and ulcerations in the skin*



*Fig.5 Ulceration and sloughing of skin caused by damage to blood vessels in the skin*

Photographs courtesy of Ana Nunes DSPA-DGAV, Campo Grande n.º 501700-093 Lisboa.

[www.dgav.pt](http://www.dgav.pt)